

Quality Of Life Case Study

Christine Wilson, Community Stoma Nurse Specialist, Hartlepool & North Tees



This case study represents my experience in using Dansac NovaLife TRE soft convex barrier with this specific patient and may not necessarily be replicated.

Patient Overview

The patient is a 72 year married woman. She presented with a breakdown and pruritus to her peristomal skin following chemotherapy treatment.

Patient History

The patient had a colostomy following a recent cancer diagnosis that required colorectal surgery. During post-operative recovery, she managed her stoma care independently with no complications. The following year, the patient commenced chemotherapy treatment and experienced a sudden breakdown to her peristomal skin.

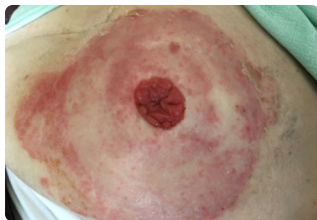
Patients with sore peristomal skin are seen and assessed by the stoma care nurse. The cause and contributing factors are identified and an appropriate treatment regime is agreed. The stoma nurse educates the patient to promote participation of the treatment regime to facilitate optimal skin healing (ASCN 2019).

Intervention

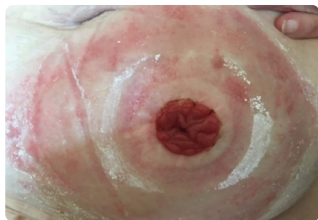A home visit was arranged and clinical assessment utilising the DET score was taken as well as the patient's past medical history and medications. The patient reported that she had noticed initial skin changes for several weeks prior to requesting an assessment.

This ostomy skin tool is a standardized and validated measuring instrument for assessing the extent and severity of peristomal skin change in terms of discolouration (D), erosion (E), and tissue overgrowth (T) (DET) (Martins ET AL 2010).

The patient was diagnosed with allergic contact dermatitis to the peristomal skin. Lyon ET AL (2001) describes allergic contact dermatitis as a rash consisting of coalescing vesicles and excoriated erythema.



Initial assessment prior to treatment. Classic allergic contact dermatitis distributed to the area of skin beneath base plate.



One week post Dansac NovaLife TRE barrier - visual improvement in skin health.

References

- Lyon. C. Smith. A (2001) Hampshire. Thompson Publications. Abdominal Stomas and their Skin Disorders. P41-42.
- Martins L; Ayello EA; Claessens I; Hansen AS; Poulsen LH; Sibbald RG; Jemec. (2010) The Ostomy Skin Tool: tracking peristomal skin changes. British Journal of Nursing. V 19. P960 – 964.

CE Prior to use, be sure to read the Instructions for Use for information regarding Intended Use, Contraindications, Warnings, Precautions, and Instructions.

The Dansac logo, NovaLife, and TRE are trademarks of Dansac A/S. ©2020 Dansac A/S

On initial assessment, the patient's DET score was 6. (score 3 for discoloration with more than 50% of the peristomal skin affected and score 3 for erosion with more than 50% of the peristomal skin affected).

The patient found the pruritus extremely distressing. She was not sleeping well and her general mood was low, especially as she was also dealing with the cancer diagnosis. Her husband was very concerned for her welfare.

A care plan and treatment plan was devised and immediately implemented, with weekly assessment visits arranged. I advised the patient to discontinue her current stoma pouch and to trial the Dansac NovaLife TRE soft convex pouch as I felt this would help maintain the natural PH levels of her skin and the skin integrity in the longer term. I provided the patient with samples of the Dansac NovaLife TRE soft convex pouch and recommended that she changed the pouches daily.

“ The patient was greatly relieved, her mood improved and she felt more able to participate in daily activities. ”

Conclusion

Within one week, the patient's peristomal skin was less inflamed and her pruritus greatly reduced as part of the overall care plan. The DET score was 3 (some discoloration still present). Two weeks later, the patient's peristomal skin had further visually improved and no pruritus was present. Both the patient and her husband were greatly relieved. The patient's mood improved and she felt more able to participate in daily activities.

Key Learnings

- Be aware of the patient's quality of life and how stoma care nurses can make a direct and positive impact
- Encourage patients to contact their stoma nurse as soon as they notice any changes
- Spend time educating patients and their carers on skin health
- Be mindful of other life challenges they may be facing
- Ensure all patients have an annual review

About Dansac NovaLife TRE

Living with a stoma does not have to mean accepting peristomal skin complications. Helping the skin around the stoma stay healthy goes a long way in enhancing the quality of people's lives.

The **Dansac NovaLife TRE** ostomy barrier is designed to help keep skin naturally healthy with 3 levels of protection:

Adhesion, Absorption and pH Balance.

The best skin is healthy skin.

For more information, contact your local representative.

